Sonographically Guided Cryoneurolysis

Preliminary Experience and Clinical Outcomes

Talia Friedman, MD, Daniel Richman, MD, Ronald Adler, MD, PhD

Chronic peripheral nerve pain is a common problem that can arise from numerous causes, for which neurolysis is a therapeutic option. It is postulated that cryotherapy will have less adverse events than other methods of nerve ablation. A retrospective case series review was performed in patients who had undergone sonographically guided cryoneurolysis for Morton neuromas, postsurgical and posttraumatic neuromas, and idiopathic neuralgia. Fifteen of 20 patients had a positive response to cryoneurolysis, as did 2 of 4 patients with borderline symptoms for chronic regional pain syndrome. In view of our positive results, we believe that cryoneurolysis should be considered a reasonable option in performing neurolytic therapy.

Key Words—cryoneurolysis; cryotherapy; neuroma; pain; peripheral neuritis

Chronic peripheral nerve pain is a common problem that can arise from numerous causes, including surgery, trauma, and a neuroma, or it can be idiopathic. Treatment of refractory pain has been attempted using surgical and various percutaneous procedures, including radiofrequency and alcohol ablation; however, complications can occur with these procedures, including neuritis and neuroma formation.[1] Pulsed radiofrequency ablation, which is postulated to be safer than traditional radiofrequency ablation, is currently under investigation. It has been shown to be efficacious for cervical radicular pain, but in lumbar facet arthropathy and trigeminal neuropathy, results were not equal to those of traditional radiofrequency ablation.[2]

In living tissue when temperatures reach between 0°C and –20°C, extracellular water freezes, resulting in a hyperosmotic environment, which leads to cell dehydration. At temperatures below –20°C, intracellular ice forms, the major mechanism for cell injury in cryoneurolysis.[3] In an animal model, controlled cryoinjury to nerves resulted in total degeneration of the myelin fibers, whereas nonmyelin fibers and vessels were less affected.[4] Regeneration follows the injury, as the Schwann cell basal lamina is spared and provides the structure for regeneration.[5] When the endoneurium is spared, neuroma formation does not occur.[6] Early regeneration begins 2 weeks after freezing, with the time to total regeneration related to the rate of axonal regrowth and the distance of the cryo-produced lesion from the end organ.[4] Given these circumstances, it is postulated that cryotherapy will have less adverse events than other methods of nerve ablation.

Received April 19, 2012, from the Department of Radiology and Imaging (T.F.) and Pain Management Center (D.R.), Hospital for Special Surgery, New York, New York USA; and Department of Radiology, New York University, New York, New York USA (R.A.). Revision requested May 10, 2012. Revised manuscript accepted for publication June 7, 2012.

Address correspondence to Ronald Adler, MD, PhD, Department of Radiology, New York University, 333 E 38th St, New York, NY 10016 USA.

Cryoneurolysis (also known as cryoablation, cryolysis, or cryoanalgesia) for peripheral neuritis was first described in 1976 (performed open or under direct surgical visualization).[7] Despite the time since the first description and the fact that no cases of permanent nerve damage from cryotherapy have been reported,[5] cryolysis has not been widely used, apart from its use in post-thoracotomy pain, with few articles published on its use for peripheral neuritis. In addition, despite the knowledge that proper probe placement is critical to achieve good outcomes,[5] sonographic guidance for cryoneurolysis of peripheral nerves has only been described in 2 case studies.[8,9]

Sonographic guidance is extensively used for minimally invasive percutaneous procedures, including steroid injections, biopsies, and aspirations.[10,11] Sonography offers many advantages, including direct visualization of the probe, nerve, and ice ball, all in real time with a lack of ionizing radiation. We describe our experience performing these procedures, which has been a collaborative effort between the ultrasound division and the pain management service. We have found that patients undergoing cryolysis have largely reported pain relief and improvement in function; no serious complications have yet been identified.

Materials and Methods

Study Design

This study, which was approved by our Institutional Review Board, involved a retrospective case series review of the results of sonographically guided cryoneurolysis for painful neuromas and peripheral neuritis. All patients who received sonographically guided cryoneurolysis performed by the authors from January 2007 to October 2011 were identified. The patients were referred for pain that was refractory to multiple conservative measures, including physiotherapy and steroid injections. Eleven patients had prior surgery without relief.

The patient charts were examined, and the severity and duration of their pain before cryoneurolysis were recorded, as were their prior treatments and outcomes. Most patients filled out standardized consult forms before the procedure, which included a visual analog scale score and a list of activities of daily living, including the distance they are able to walk and the time they are able to stand. Where available, those with a pretreatment visual analog scale score of 1 to 3 were considered to have mild pain, those with a score of 3 to 6 moderate pain, and those with a score of 7 to 10 severe pain. When a visual analog scale score was unavailable the patient's own descriptors of pain were used to categorize the pain as mild, moderate, or severe.

The charts were examined to determine the degree of pain relief and its duration after cryoneurolysis. The patients were assessed before and after treatment by the same anesthesiologist who performed the treatment in conjunction with radiology. All patients were scheduled for follow-up at 4 to 6 weeks. Follow-up before and after this time was variable because it was at the patient's discretion. Patient responses were categorized as no, mild, moderate, and marked pain relief.

Patients

A total of 52 patients were identified. Sixteen patients were excluded for preexisting complex regional pain syndrome because these patients have a complex clinical picture. Four patients had equivocal symptoms of complex regional pain syndrome and had follow-up information. They are included but discussed separately. Of the remaining 32 patients, 20 had follow-up information available. Fifteen patients were female and 5 male. The patients ranged in age from 18 to 79 years (mean age, 49 years). Patient charts were reviewed to assess the efficacy of the procedure, with pain responses categorized as described above.

The 20 patients fell into 1 of 3 categories. Group A consisted of 5 patients with painful Morton neuromas (all women; age range, 47–60 years; mean age, 55 years). Group B consisted of 12 patients with stump neuromas secondary to surgery or trauma (8 women and 4 men; age range, 18–79 years; mean age, 47 years). Group C consisted of 3 patients with peripheral neuritis but no visible anatomic lesion (2 women and 1 man; age range, 21–71 years; mean age, 47 years). The 4 patients with borderline symptoms for complex regional pain syndrome were all female and ranged in age from 19 to 61 years (mean age, 41 years).

Sixteen of the patients without complex regional pain syndrome received sonographically guided anesthetic injections for diagnostic purposes before cryoneurolysis, as did all 4 patients with borderline complex regional pain symptoms. Two patients did not receive diagnostic injections because they had previously received therapeutic sonographically guided anesthetic injections with cortisone and onabotulinumtoxin A, respectively. All patients had at least moderate pain improvement after anesthetic injection.

Technique

Immediately before cryoneurolysis, patients were premedicated with 1 g of intravenous cefazolin (vancomycin was used in those with allergies). Most patients also received 1.5 to 2 mg of oral lorazepam and 5/325 mg of oral oxycodone/-acetaminophen. At their request, 1 patient received spinal anesthesia before treatment, and 1 received intravenous

sedation. Patients were positioned supine, prone, or on their side according to the lesion location. Baseline scans were performed with an iU22 scanner (Philips Healthcare, Bothell, WA) to identify the specific target nerve or neuroma and to plan an appropriate trajectory for the cryoprobe. An L12-5 transducer was used for deep structures, whereas an L15-7 transducer was used for superficial structures. All injections were performed by a freehand technique.

The cryotherapy machine used was a Frigitronics CE 2000 (Cooper Surgical, Inc, Trumbull, CT). The coolant used was nitrous oxide, although carbon dioxide can be substituted with the same effects.[4] Argon as a coolant has been shown to have advantages in tumor and cardiac applications, including faster freeze and thaw cycles, faster halting of the freeze cycle, colder temperatures, and smaller probe sizes[3,12]; however, its use has not yet been documented for peripheral cryoneurolysis. Unlike in tumor treatment, only a single freeze cycle is performed, and no thaw cycles are used. Current probe sizes are adequate for treatment of small peripheral lesions. Given the absence of a thaw cycle, there is no additional advantage gained in using argon for peripheral cryoneurolysis. The cryoprobe used was a Cooper Surgical 228 probe, which is a 17-gauge trochar probe. The cutting edge of a trochar probe is preferred because it more easily passes through tissue, rather than the blunt edge of a rounded probe. An image of the cryoprobe with an ice ball is shown in Figure 1, and an image of the cryoprobe in place for treatment of a sural neuroma is shown in Figure 2.

A proximal nerve block with 0.75% bupivacaine was performed in most patients at the start of the procedure to provide regional anesthesia for the duration of the procedure and short-term periprocedural pain relief. The volume varied (5–30 mL) depending on the site of the nerve block. Images from the nerve block performed in patient 21 are shown in Figure 3. The cryogenic probe was tested before placement in each case. A small amount of 1% lidocaine was then used as a local anesthetic, and a number 11 blade

Figure 1. Cryoprobe. An ice ball formed after placing the cryoprobe in sterile lidocaine is present at the tip.



Figure 2. The ultrasound probe is held by the radiologist and guides the cryoprobe held by the anesthesiologist during the treatment of a sural neuroma.

Figure 3. **A** and **B**, Images from the nerve block performed in patient 21. The superficial peroneal nerve (large arrow) is shown surrounded by the anechoic fluid of the lidocaine/bupivacaine mixture (F). Note the fascicular architecture of the nerve. The needle is below the nerve (small arrows in **A**).

A

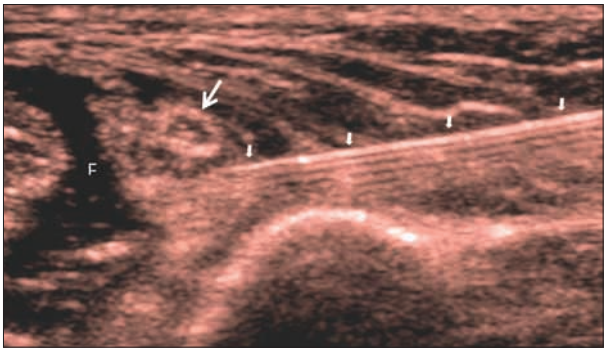

B

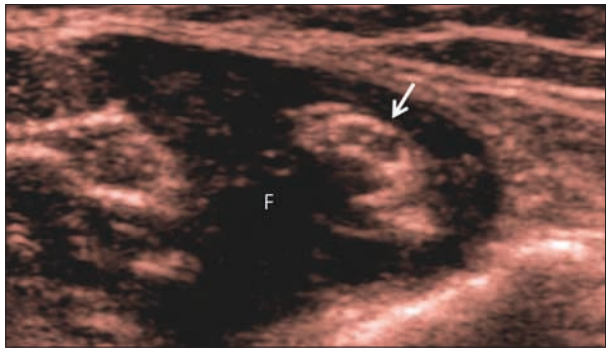

was used to perform a small puncture. Through the puncture, a 12-gauge Jelco needle (Smiths Medical, Dublin, OH) was used to create a small tunnel, and the 17-gauge trochar tip cryoprobe was advanced under sonographic visualization using a coaxial technique until just proximal to the nerve or into the neuroma. A sheath was left around the cryoprobe to protect the skin and nontarget tissues. In cases without a visible lesion, an electric stimulator was used to confirm correct positioning. Figure 2 shows a cryoprobe in place. Once in position, the cryoprobe was activated; the temperature was decreased to –75°C; and ice balls were created. Two to 4 ice balls were created, with larger lesions requiring more ice balls, until the lesion was entirely surrounded. The number of applications was determined empirically as needed to surround the entire lesion; the probe was repositioned slightly to create contiguous ice balls (Figure 4E). When no lesion was visualized, at least 3 contiguous ice balls were created along the nerve. Table 1 lists the number of ice balls and duration of the freeze cycles for each patient's lesion. The ice balls display posterior acoustic shadowing as they form (Figure 4D). The ice balls measure on average 1.1 cm (range, 0.8–1.3 cm).

Patients were discharged when they had recovered from anesthesia with standardized post-procedure instructions and were scheduled for clinical follow-up with pain management in 4 to 6 weeks.

Results

Overall, 15 of the 20 patients without symptoms of chronic regional pain syndrome had a positive response to cryoneurolysis, and 5 had no relief (including 1 patient who had both feet treated). Three of the 5 unresponsive patients went on to further surgical procedures; it is unknown whether they provided relief. Further information regarding the remaining 2 patients was not available. Of those with a positive response, 11 patients had marked or total pain relief; 3 had moderate relief; and 1 had mild relief.

Of the 5 patients with Morton neuromas, only 1 patient had no relief. Of the remaining 4 patients with positive responses, 3 had marked relief; 1 had moderate relief; and 1 had no relief. Follow-up times ranged from 6 weeks to 14 months (mean, 14 weeks). The results are summarized in Table 2. Images from the treatment of patient 12's left-sided neuroma are shown in Figure 4.

Of the 3 patients in whom no lesions could be visualized, 2 had marked relief, and 1 had no relief. One patient with marked relief was a professional ballet dancer who had been unable to dance because of her pain. After cryoneurolysis, she returned to professional ballet. She returned for a second treatment, although no follow-up of that cryoneurolysis was available. Follow-up times ranged from 4 to 8 months (mean, 5.6 months) The results for this group of patients are summarized in Table 3.

Of the 12 patients with posttraumatic or postsurgical lesions, 6 had marked relief; 2 had moderate relief; 1 had mild relief; and 3 had no relief. Follow-up times ranged from 2 weeks to 3 years 2 months (mean, 6.3 months). The results for this group of patients are summarized in Table 4. Images from the treatment of patients 17 and 7 are shown in Figures 5 and 6.

Of the 4 patients with borderline symptoms for the diagnosis of complex regional pain syndrome, 2 had a positive response, and 2 did not have relief. Follow-up times ranged from 1 month to 1 year (mean, 4 months). The results for this group of patients are summarized in Table 5.

Four of the 5 nonresponsive patients without complex regional pain symptoms had pain that was severe, and 1 had pain that was moderate. Two patients had temporary worsening of pain, 1 for several days (patient 10) and 1 for 2 weeks (patient 17), followed by marked relief of their initial pain. One patient noted worsening in his pain after cyroneurolysis, which did not improve (patient 16); he went on to surgical excision of his stump neuroma.

Of particular note, 7 patients were satisfied enough with the results of their cryoneurolysis to return for a second treatment of the same lesion. Examination at the time of the second treatment did not reveal clear changes in the appearance of the nerves or neuromas. In this group, the duration of pain relief ranged from 5 months to 3 years 2 months (mean, 10 months). Two additional patients went on to have cyroneurolysis in a second area (patients 2 and 7).

Discussion

As with all invasive procedures, sonographically guided cryoneurolysis carries the risks of bleeding and infection. In our series, only minor bleeding at the puncture site occurred. There were no cases of infection. Thrombosis is a potential complication. No cases occurred in our series. A complication unique to cryoneurolysis is skin ischemia, which can lead to skin necrosis. The risk is higher for more superficial lesions. While performing cyroneurolysis, skin blanching can be seen, indicating early ischemia. The blanching is reversible, and when we observed it, the freeze cycle was terminated. No cases of skin necrosis occurred in our series. Apart from 1 reported patient in whom neuritis developed,[13] no complications of cyroneurolysis for peripheral pain have been reported.[5]

The safety and efficacy of cryoneurolysis for relief of post-thoracotomy pain have been well documented.[5,14,15] Hodor et al[16] described a single case study of cryoneurolysis of a posttraumatic intermetatarsal neuroma, in which the patient had total relief at 6 months. The neuroma was localized with a nerve stimulator. Using a nerve stimulator, Caporusso et al[17] treated 20 patients with painful intermetatarsal neuromas and reported that 38.7% had total relief, and 42.5% had partial relief at 1 year. Wang[18] reported between 1 to 6 months of relief in 6 of 12 patients who had various peripheral nerves treated in the upper and lower extremities. Wang[18] also used a nerve stimulator to identify

Figure 4. Images from patient 12 (see Tables 1 and 2), a 47-year-old woman with painful Morton neuromas. **A**, Longitudinal sonogram taken from the plantar surface of the foot shows a well-defined 10 × 7-mm hypoechoic nodule in the third web space, consistent with a Morton neuroma (arrows). **B**, Proton density image taken in the axial plane of the foot shows an intermediate signal nodule in the third web space, corresponding to the sonographic findings and consistent with a Morton neuroma. **C**, The cryoprobe (small arrows) is placed under the third web space neuroma (large arrows) before beginning the first freeze cycle. **D**, At the end of the freeze cycle, the superficial margin of the ice ball is shown (large arrows) with prominent posterior shadowing (S). As the ice ball forms, the shadowing becomes more marked. The cryoprobe remains in place (small arrows). **E**, After the second freeze cycle, 2 ice balls are now present side by side. The superficial contours of the ice balls (large arrows) and the prominent posterior showing caused by the ice balls (S1 and S2) are shown. The cryoprobe remains in place (small arrows).

A

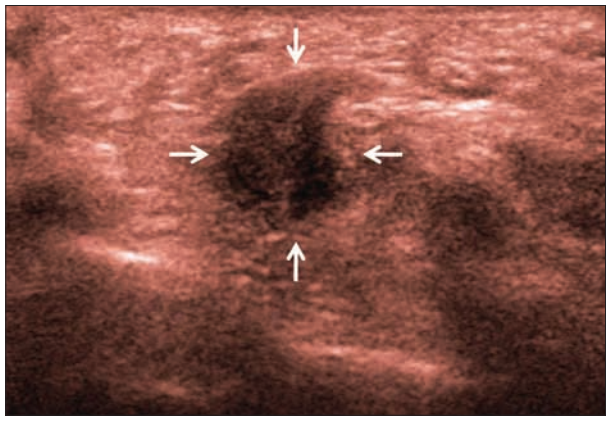

B

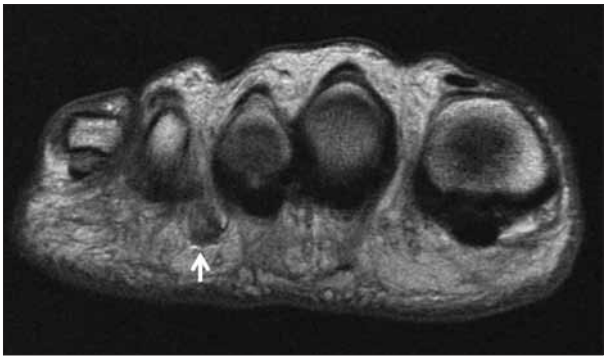

C

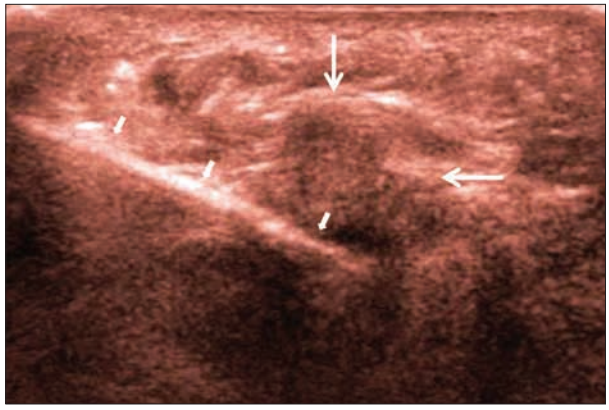

D

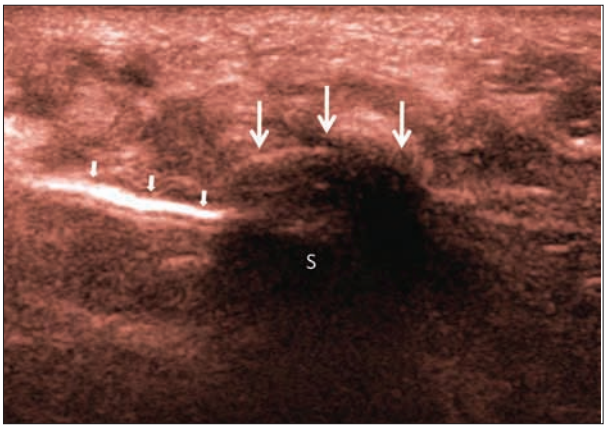

E

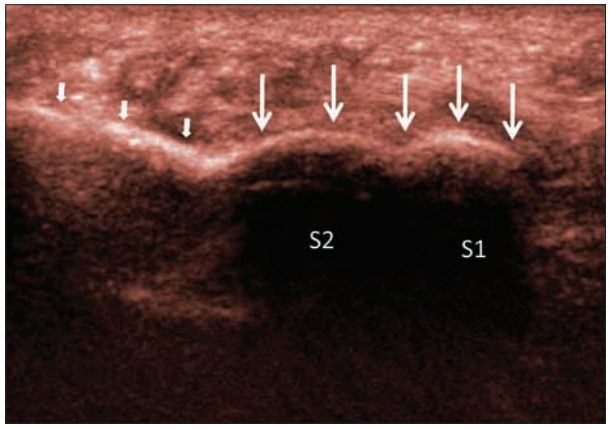

the nerve of concern. Two studies assessed cryoneurolysis for plantar fascia pain, placing the probe at the site of maximal tenderness. Allen et al[19] treated 58 patients, with 90% reporting decreased pain at 1 year and 54% being entirely pain free at that time. Cavazos et al[20] had a 77.4% positive response rate in 137 feet, with positive responders having

Table 1. Lesion Descriptions, Number of Ice Balls per Lesion, and Lengths of the Freeze Cycles

Patient	Lesion	No. of Ice Balls Created × Length of Freeze Cycles
1	3rd web space neuroma, 6 × 4 mm	2 × 2-min cycles
2	2nd web space neuroma (right), 9.5 × 8.5 mm	1 × 3-min cycles
2	3rd web space neuroma (right), 8.0 × 6.0 mm	1 × 3-min cycles
3	Left medial nerve (no distinct lesion)	4 × 3-min cycles along the distal medial plantar nerve
4	2nd web space neuroma, 5.8 × 3 mm	2 × 3-min cycles
4	3rd web space neuroma, 13.0 × 6.5 mm	3 × 3-min cycles
5	Stump neuroma in the 3rd web space, 9 × 9 mm	3 × 3-min cycles
6	Scar tissue at the medial plantar nerve	4 × 3-min cycles at the distal medial plantar nerve at the level of scarring
7	Stump neuroma at the peroneal nerve stump, 7 × 5 × 17 mm	2 × 3-min cycles at the common peroneal nerve, 4 × 3-min cycles into the stump neuroma
8	Scarring of the sural nerve	3 × 3-min cycles along the sural nerve
9	2nd web space neuroma, 4.5 × 4 mm	1 × 3-min cycles, 1 × 2-min cycles
9	3rd web space neuroma, 8.5 × 4.5 mm	2 × 3-min cycles
10	Scar at the distal medial plantar nerve	4 × 2.5-min cycles along the plantar nerve
11	Scar around the sural nerve	2 × 3-min cycles, additional shorter cycles
12	2nd web space Morton neuroma (right), 5.5 × 3.5 mm	1 × 3-min cycles
12	3rd web space Morton neuroma (right), 9.5 × 7.5 mm	1 × 3-min cycles, 1 × 2-min cycles
12	3rd web space Morton neuroma (left), 10.0 × 7. 0 mm	2 × 3-min cycles
13	Scarring of the medial plantar nerve	4 × 3-min cycles
14	Baxter nerve neuritis (no visualized lesion)	3 × 3-min cycles
15	Medial plantar nerve neuritis (no visualized lesion)	3 × 3-min cycles at the medial plantar nerve at the level of the knot of Henry
16	Sciatic stump neuroma	2 × 3-min cycles in the neuroma, 3 × 3-min cycles in the focal hypoechoic area in the posterolateral aspect of the stump (possible secondary stump neuroma)
17	Saphenous neuroma	3 × 3-min cycles, each at a different level
18	Scar around the lateral plantar nerve at the tarsal tunnel	2 × 3-min cycles
19	Saphenous nerve stump neuroma	2 × 2-min cycles at the neuroma, 3 × 3-min cycles distal at the saphenous nerve
20	Lateral plantar nerve, poorly defined scarring	3 × 2.5-min cycles
21[a]	Scarring of the peroneal nerve at the level of the lateral malleolus	3 × 3-min cycles at different locations near the site of scarring
22[a]	No visualized abnormality	4 × 3-min cycles the along sural nerve at the lateral malleolus (site of maximal pain)
23[a]	Scarring of the peroneal nerve at the tibiotalar joint	3 × 2-min cycles at the site of scarring
24[a]	Scar encasing an interdigital sensory nerve	4 × 3-min cycles

[a]These patients had borderline symptoms for the diagnosis of complex regional pain syndrome.

Table 2. Patients with Morton Neuromas

Patient	Pretreatment Pain	Treatment Response	Follow-up Duration
1	Severe	Marked	6 wk
2	Severe	Marked	14 mo (56 wk) of pain relief
4	Moderate	Moderate	4 wk
9	Moderate	Marked	10 wk
12 (both feet)	Moderate	None	4 wk

Patient numbers correspond to those in Table 1. Unless otherwise specified, longer follow-up was not available.

significantly lower pain scores at 3 weeks and at 2 years. In their case report, Rhame et al[9] described 3 months of pain relief after sonographically guided cryoneurolysis of a sural neuroma, with several 3-month periods of relief over the 3-year treatment period. The patient reported by Campos et al[8] had at least 3 months of relief after sonographically guided cryoneurolysis of the genitofemoral nerve.

Ramamurthy et al[13] studied the effects of phenol and cryoneurolysis for peripheral nerve blocks. They concluded that neither phenol nor cryoneurolysis provided pain relief for most of their 28 patients. Their patients were randomized to either phenol or cryoneurolysis, with only 27% of all patients having a positive response. No image guidance was used, however, and the nerve was localized with a nerve stimulator. They postulated that several factors may have accounted for the cryoneurolysis failures, including a large probe size causing further trauma and the possibility that the ice ball pushed the nerve away from the treatment field as it formed.[13] Ramamurthy et al[13] included patients with complex regional pain syndrome in their study, whose complex clinical pictures may make them less responsive to cryoneurolysis.

Sonographic guidance allows direct visualization of the nerve and its relationship with the ice ball, ensuring adequate treatment of the nerve. One patient in our study received blind cryoneurolysis before sonographically guided cryoneurolysis. She had no relief with the blind cryoneurolysis but had marked relief with the sonographically guided cryoneurolysis for at least 3 months.

In our patient cohort, 7 patients, who were refractory to other conservative therapies, returned for a second treatment of the same lesion. In this group, the duration of pain relief ranged from 5 months to 3 years 2 months (mean, 10 months).

There were limitations to this study. Only the superficial margin of the ice ball was evident because of dense posterior acoustic shadowing. One can estimate the size of the ice ball given the superficial margin, assuming it forms a symmetric ellipsoid. In addition, one can scan the nerve proximal and distal to the ice to see the entry and exit points of a nerve (Figure 6C).

Only a small cohort of patients was studied, albeit with a relatively diverse collection of abnormalities. The retrospective nature of the study and the fact that follow-up after 6 weeks was variable resulted in a relatively broad range of time points for follow-up data. In several cases, only a 4- or 6-week evaluation was available. Because the same anesthesiologist who initially assessed the patients and helped administer treatment performed the follow-up, individual bias could have been present. The retrospective nature of the study also precluded the use of a control group; however, there was a measure of internal control because all patients were refractory to multiple prior conservative measures such as physiotherapy and steroid injections.

Table 3. Patients in Whom no Lesion Could Be Visualized

Patient	Pretreatment Pain	Treatment Response	Follow-up Duration
3	Moderate	Marked	5 mo of relief, returned for 2nd cryoneurolysis
14	Severe	None	4 mo
15	Moderate	Marked	8 mo of relief, returned for 2nd cryoneurolysis

Patient numbers correspond to those in Table 1. Unless otherwise specified, longer follow-up was not available.

Table 4. Patients With Posttraumatic and Postsurgical Lesions

Patient	Pretreatment Pain	Treatment Response	Follow-up Duration
5	Severe	None	2 wk
6	Moderate	Mild	7 wk
7	Moderate	Marked	17 wk
8	Moderate	Marked	6 mo of relief , returned for 2nd cryoneurolysis
10	Moderate	Moderate	6 wk
11	Moderate	Moderate	Moderate relief at 3 wk, no relief at 4 mo
13	Moderate	Marked	8 mo of relief, returned for 2nd cryoneurolysis
16	Moderate	None	1 mo
17	Severe	Marked	3 y 2 mo of relief, returned for 2nd cryoneurolysis
18	Severe	None	3 wk
19	Moderate	Marked	6 mo of relief, returned for 2nd cryoneurolysis
20	Severe	Marked	11 wk

Patient numbers correspond to those in Table 1. Unless otherwise specified, longer follow-up was not available.

A

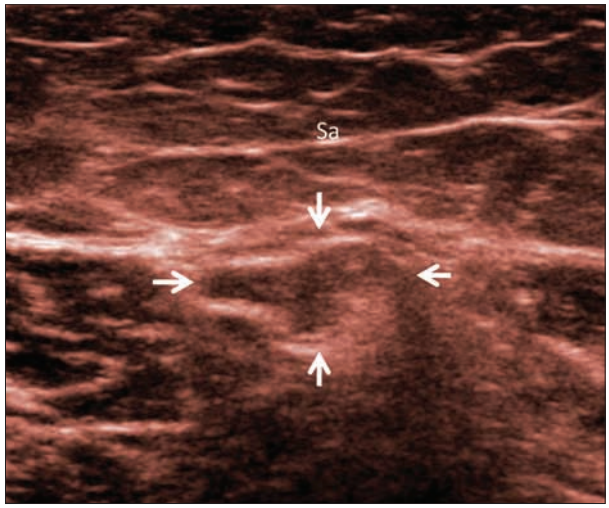

B

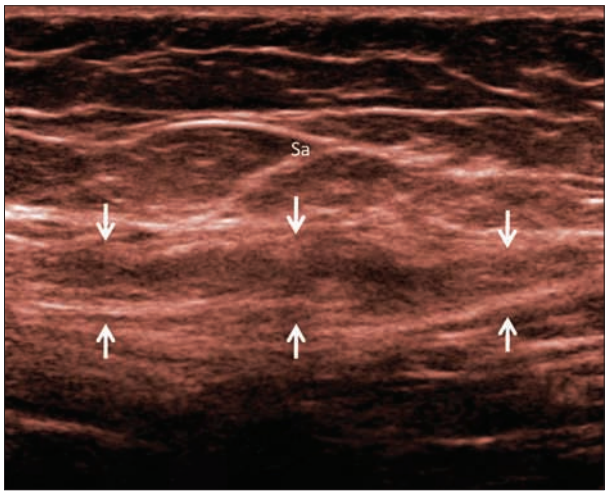

D

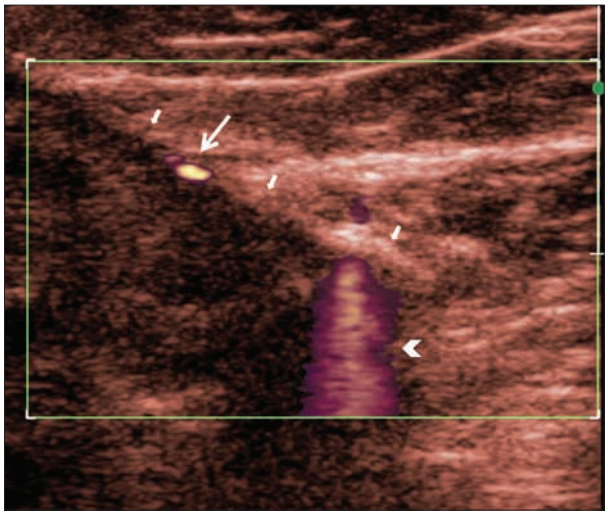

Figure 5. Images from patient 17 (see Tables 1 and 4), a 26-year-old woman with a saphenous nerve neuroma. **A** and **B**, Transverse (**A**) and longitudinal (**B**) sonograms show a large irregular but well-defined hypoechoic nodule deep to the sartorius muscle (Sa) in the region of the saphenous nerve, reflecting a posttraumatic neuroma (arrows). **C**, Axial proton density magnetic resonance image shows the saphenous nerve distorted and encased in intermediate signal material (arrows), in keeping with scar tissue and a posttraumatic neuroma. The findings correspond to those seen on sonography. A vitamin E capsule (E) indicates the site of the patient's pain. **D**, Power Doppler sonogram shows a ring-down artifact (arrowhead) caused by ice crystals forming at the beginning of the freeze cycle. Gas bubbles (large arrow) in the cryoprobe (small arrows) are also shown. **E**, At the end of the freeze cycle, the superficial margin of the ice ball is shown (large arrows) with prominent posterior shadowing (S). The cryoprobe remains in place (small arrows).

C

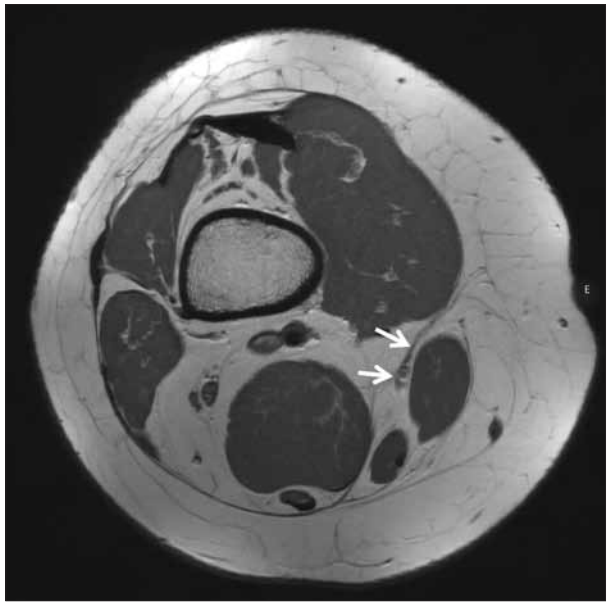

E

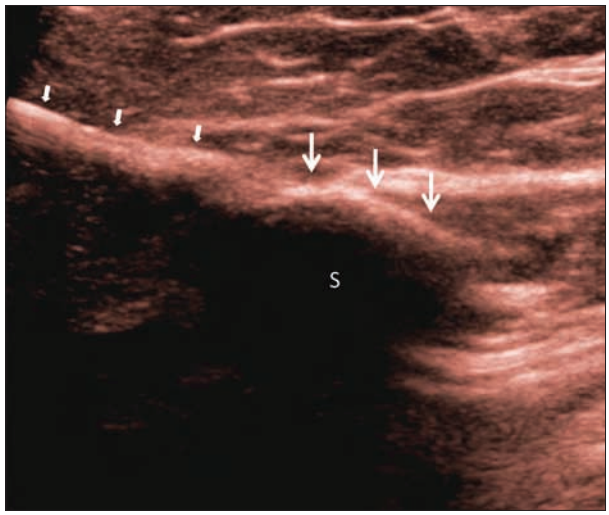

Although prospective studies would be of value, given the overall positive results in our group of patients and the proven safety and efficacy of cryoneurolysis for post-thoracotomy pain, we suggest that sonographically guided cryoneurolysis should be considered as an alternative method for treatment of peripheral pain.

In conclusion, we have described our initial experience with performing sonographically guided cryoneurolysis in a small cohort of patients with peripheral nerve lesions. In our experience to date, it is a safe procedure that can result in substantial pain reduction and improvement in the quality of life.

A

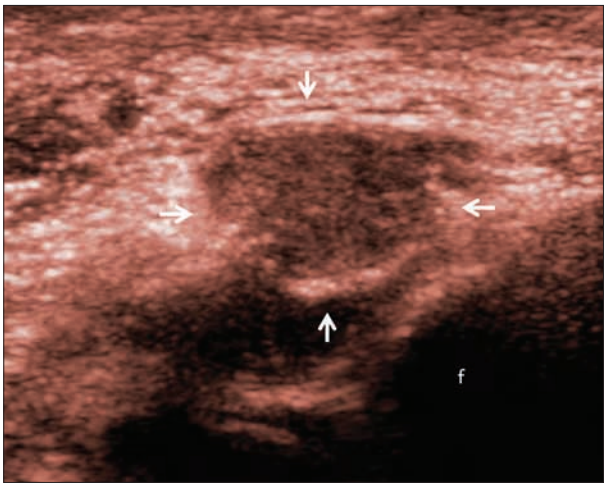

B

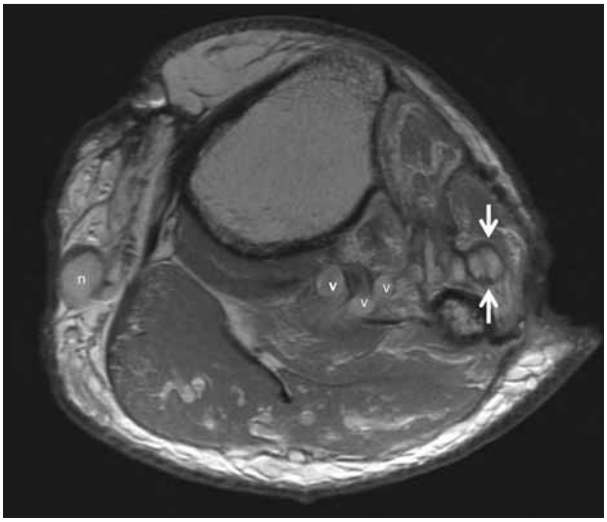

Figure 6. Images from patient 7 (see Tables 1 and 4), a 52-year-old woman with a below-the-knee amputation who wears a specialized prosthesis for running. She had pain localized to the anterolateral aspect of the stump, preventing her from running. **A**, Large hypoechoic nodule (arrows) anterior to the fibula (f) arising from the common peroneal nerve, consistent with a stump neuroma. **B**, Axial proton density magnetic resonance image shows multiple hyperintense nodules arising from several nerves, consistent with multiple stump neuromas. A nodule arises from the common peroneal nerve (arrows), corresponding to the neuroma seen on sonography and corresponding to the site of the patient's maximum pain. She was pleased with the results of her cyroneurolysis and went on to have cryoneurolysis of the tibial neuroma (n) at a later date. Multiple varicosities are also shown (v). **C**, After a freeze cycle at the common peroneal nerve proximal to the neuroma, the superficial margin of the ice ball can is shown (thin arrows) with prominent posterior shadowing (S). The common peroneal nerve is shown entering and exiting the ice ball (thick arrows). Multiple freeze cycles were then performed at the neuroma (not shown).

C

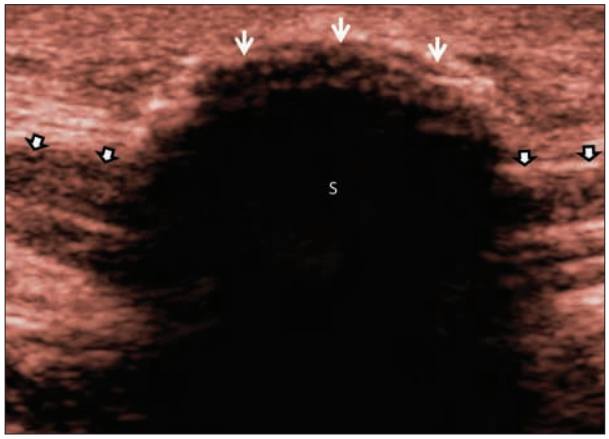

Table 5. Patients With Borderline Symptoms for the Diagnosis of Complex Regional Pain Syndrome

Patient	Pretreatment Pain	Treatment Response	Follow-up Duration
21	Severe	Marked	1 y, returned for second cryoneurolysis
22	Severe	None	1 mo
23	Severe	Marked	2 mo
24	Moderate	None	1 mo

Patient numbers correspond to those in Table 1. Unless otherwise specified, longer follow-up was not available.

References

1. Wu H, Groner J. Pulsed radiofrequency treatment of articular branches of the obturator and femoral nerves for management of hip joint pain. *Pain Pract* 2007; 7:341–344.
2. Chua NHL, Vissers KC, Sluijter ME. Pulsed radiofrequency treatment in interventional pain management: mechanisms and potential indications: a review. *Acta Neurochir (Wien)* 2011; 153:763–771.
3. Theodorescu D. Cancer cryotherapy: evolution and biology. *Rev Urol* 2004; 6(suppl 4):S9–S19.
4. Fasano VA, Peirone SM, Zeme S, et al. Cryoanalgesia: ultrastructural study on cryolytic lesion of sciatic nerve in rat and rabbit. *Acta Neurochir Suppl (Wien)* 1987; 39:177–180.
5. Trescot AM. Cryoanalgesia in interventional pain management. *Pain Physician* 2003; 6:345–360.
6. Sunderland S. *Nerves and Nerve Injuries.* Edinburgh, Scotland: E & S Livingstone; 1968:18040.
7. Lloyd JW, Barnard JD, Glynn CJ. Cryoanalgesia: a new approach to pain relief. *Lancet* 1976; 2:932–934.
8. Campos NA, Chiles JH, Plunkett AR. Ultrasound-guided cryoablation of genitofemoral nerve for chronic inguinal pain. *Pain Physician* 2009; 12:997–1000.
9. Rhame EE, DeBonet AF, Simopoulos TT. Ultrasonographic guidance and characterization of cryoanalgesic lesions in treating a case of refractory sural neuroma. *Case Rep Anesthesiol* 2011; 2011:691478. doi:10.1155/2011//691478.
10. Adler RS, Sofka CM. Percutaneous ultrasound-guided injections in the musculoskeletal system. *Ultrasound Q* 2003; 19:3–12.
11. Sofka CM, Adler RS, Ciavarra GA, Pavlov H. Ultrasound-guided interdigital neuroma injections: short-term clinical outcomes after a single percutaneous injection—preliminary results. *HSS J* 2007; 3:44–49.
12. Zisman A, Pantuck AJ, Cohen JK, Belldegrun AS. Prostate cryoablation using direct transperineal placement of ultrathin probes through a 17-gauge brachytherapy template: technique and preliminary results. *Urology* 2001; 58:988–993.
13. Ramamurthy S, Walsh NE, Schoenfeld LS, Hoffman J. Evaluation of neurolytic blocks using phenol and cryogenic block in the management of chronic pain. *J Pain Symptom Manage* 1989; 4:72–75.
14. Moore W, Kolnick D, Tan J, Yu HS. CT guided percutaneous cryoneurolysis for post thoracotomy pain syndrome: early experience and effectiveness. *Acad Radiol* 2010; 17:603–606.
15. Johannesen N, Madsen G, Ahlburg P. Neurological sequelae after cryoanalgesia for thoracotomy pain relief. *Ann Chir Gynaecol* 1990; 79:108–109.
16. Hodor L, Barkal K, Hatch-Fox LD. Cryogenic denervation of the intermetatarsal space neuroma. *J Foot Ankle Surg* 1997; 36:311–314.
17. Caporusso EF, Fallat LM, Savoy-Moore R. Cryogenic neuroablation for the treatment of lower extremity neuromas. *J Foot Ankle Surg* 2002; 41:286–290.
18. Wang JK. Cryoanalgesia for painful peripheral nerve lesions. *Pain* 1985; 22:191–194.
19. Allen BH, Fallat LM, Schwartz SM. Cryosurgery: an innovative technique for the treatment of plantar fasciitis. *J Foot Ankle Surg* 2007; 46:75–79.
20. Cavazos GJ, Khan KH, D'Antoni AV, Harkless LB, Lopez D. Cryosurgery for the treatment of heel pain. *Foot Ankle Int* 2009; 30:500–505.